

Niels Halama¹, Ulrike Prüfer¹, Anna Frömring², Diana Beyer², Dirk Eulberg², Jarl Ulf Jungnelius², Aram Mangasarian²
¹Department of Medical Oncology and Internal Medicine VI, National Center for Tumor Diseases, University Hospital Heidelberg, Heidelberg, Germany; ²NOXXON Pharma, Berlin, Germany

BACKGROUND

NOX-A12 (olaptosed pegol) is a novel inhibitor of the chemokine CXCL12 (SDF-1) being studied for the treatment of different solid tumors. Binding of CXCL12 by NOX-A12 prevents receptor engagement of the chemokine with its receptors CXCR4 and CXCR7 and blocks formation of chemotactic CXCL12 concentration gradients by neutralization of the anchor domain. Immune checkpoint inhibitors promote T cell-mediated killing of cancer cells, but only a subset of patients benefit from the treatment. One reason for this limitation is thought to be immune cell exclusion from the tumor microenvironment (TME) by high local concentrations of CXCL12 (Feig et al. 2013, *PNAS* 110:20212). NOX-A12 synergized with PD-1 checkpoint inhibition in both a mouse model of colorectal cancer study as well as *in vitro* in tumor/stroma spheroids (Zboralski et al. 2018, *Cancer Immunol Res* 5:950). The goal of this study was to understand whether CXCL12 inhibition by NOX-A12 could reverse the immune privileged status of the TME thereby broadening the applicability of checkpoint inhibitors to the microsatellite stable population in metastatic pancreatic and colorectal cancer.

METHODS

The OPERA study (NCT03168139) is a Phase 1/2 open label clinical study to evaluate pharmacodynamic effects and safety of monotherapy with NOX-A12 and safety and efficacy of a combination of NOX-A12 with pembrolizumab in advanced microsatellite-stable (MSS), metastatic colorectal and pancreatic cancer with liver metastases. The study comprises two weeks of NOX-A12 monotherapy followed by NOX-A12 plus pembrolizumab (Fig. 1). Here we present pharmacodynamic biomarker data from for monotherapy phase with NOX-A12, as well as the clinical efficacy and safety data for the combination with pembrolizumab.

Patients received 300 mg NOX-A12 by i.v. infusion on days 1, 4, 8, and 11 of the monotherapy phase. Needle biopsies were taken from suitable liver metastases before treatment and on day 14. Collected tumor samples were assessed for immune cell infiltration by immunohistochemistry (IHC) and cytokine signature using multiplex protein analysis.

After the monotherapy phase, patients received a combination of 200 mg pembrolizumab + 300 mg NOX-A12 every three weeks until progression or intolerable toxicity. Tumor progression was monitored by MRI at 8-week intervals.

Twenty patients were recruited, thereof 11 with metastatic colorectal and 9 with metastatic pancreatic cancer (Table 1). Fifteen of the patients included (75%) are male, with a median age of 62 (colorectal) and 68 years (pancreatic).

All patients were heavily pretreated with a median of 5 lines (colorectal) and 3 lines (pancreatic) of prior systemic treatment. The best response to the last prior treatment was progressive disease for all except one of the patients. All patients had MSS cancer and thus should be non-responsive to anti-PD-1 therapy (Kalyan 2018, *J Gastrointest Oncol* 9:160; Hu 2018, *Clin Cancer Res* 24:1326).

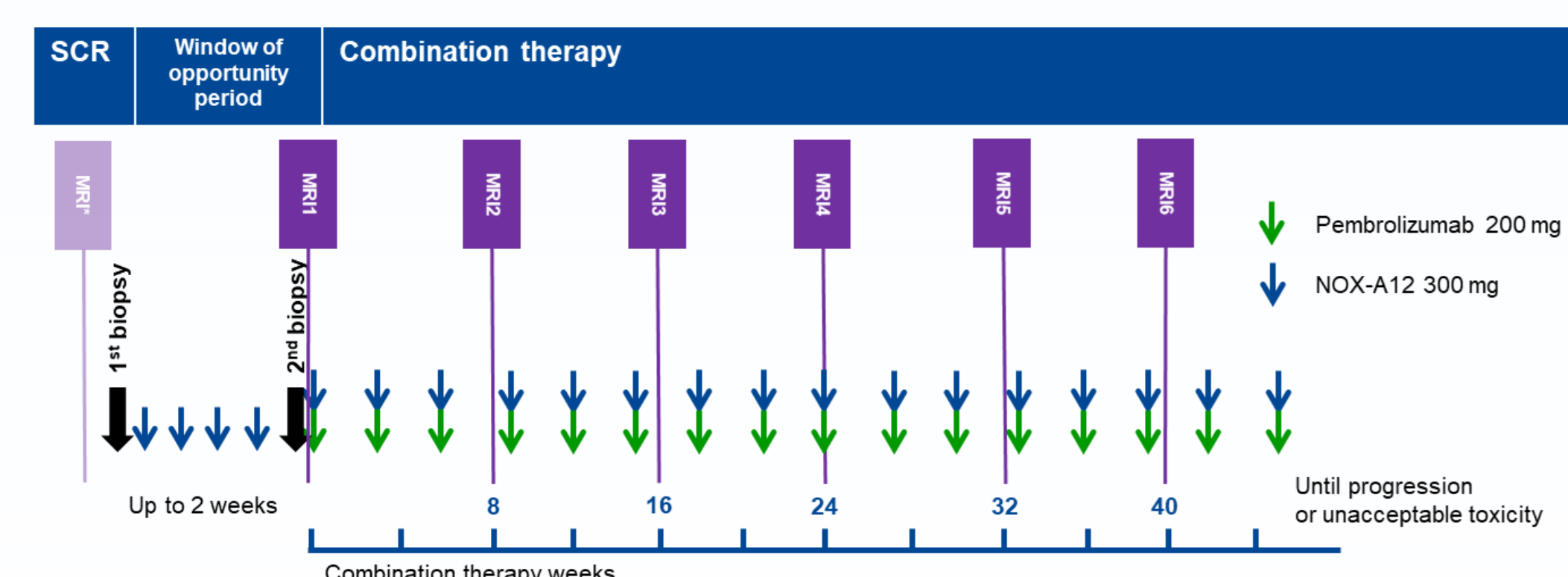


Figure 1: OPERA study design: 2 weeks of twice per week NOX-A12 monotherapy followed by combination therapy with NOX-A12 + pembrolizumab given once every 3 weeks

Table 1: Demographics

	Colorectal Cancer	Pancreatic Cancer
N	11	9
Male/Female	7 / 4	8 / 1
Age, mean (range)	63 (55 – 73)	67 (48 – 82)
Stage at study entry	100% stage IV (metastatic)	
Microsatellite status at study entry	All patients MSS	
Prior lines of systemic treatment, mean (range)*	5 (2 – 9)	3 (1 – 5)
Patients with prior surgery (# of surgeries)	7 (1 – 4)	3 (1 – 2)
Best response last treatment	PD (10), SD (1)	PD (9)
Time since last systemic prior treatment (mean)	2.0 months	1.5 months

* excluding surgery

Serial biopsies at baseline and end of NOX-A12 monotherapy suitable for (IHC) and cytokine analysis were collected and analyzed from 14 out of 20 patients. At baseline, mean T cell density at the invasive margin was 327 cells/mm², below the 600 cells/mm² predictive for a good prognosis (Halama et al. 2011, *Cancer Res* 71:5670).

Immunohistochemistry staining shows abundant presence of CXCL12 in tumors of all patients; CXCL12 positive cell types include tumor cells, monocytic-macrophage-like cells, and fibroblasts. CXCL12 levels were found to be increased in post-treatment tumor biopsies of all patients, consistent with penetration of NOX-A12 into the tumor. Greater NOX-A12-induced changes of CXCL12 levels in tissue – indicating more complete CXCL12 neutralization – correlated with an immunologically hotter tumor (Th1 immune response in tissue) and clinical benefit. Patients with more than 3-fold increase tended to present with more favorable cytokine profile or showed stable disease (Fig. 2).

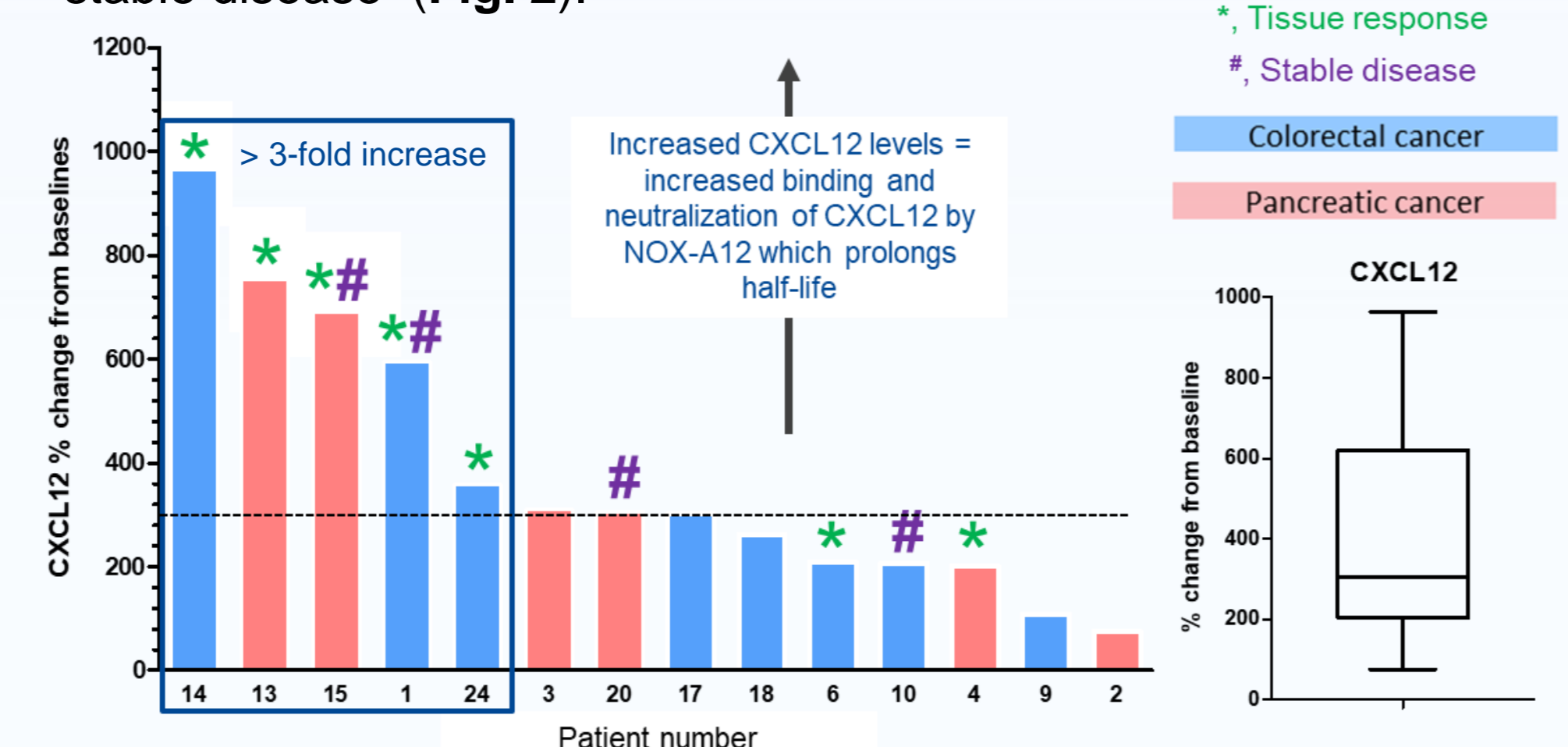


Figure 2: Increased neutralization of CXCL12 by NOX-A12 correlates with immune activation and clinical benefit

The comparison of cytokine levels in the baseline tumor biopsies with those taken after two weeks of NOX-A12 monotherapy revealed changes in markers that are consistent with a Th1 like immune response in multiple patients (Fig. 3). In particular IFN- γ , IL-2 and TNF- β were increased, accompanied by an increase of CXCL9 and/or CXCL10 indicating T cell activation and attraction in response to treatment with NOX-A12. This Th1 response was also associated with an increase of IL-16, an attractor of CD4+ T cells and marker for expansion/stimulation of helper cells.

A life expectancy of at least 3 months was stipulated in the protocol. Of the 10 patients who were alive for more than 3 months, 80% were alive past 24 weeks and 60% past 36 weeks (Fig. 4). Patient time on study and time on their previous therapy are put into perspective in Fig. 5.

As anticipated there were no observed PR or CR (RECIST) responses in these heavily pre-treated, end-stage patients. Regardless of the number of prior lines of therapy or outcome of prior therapy, 25% of patients achieved stable disease. In fact, disease stabilization following NOX-A12 + pembrolizumab therapy (27% for colorectal, 22% for pancreatic cancer) was predominantly observed in highly pretreated and rapidly progressing patients (Fig. 6). Three of the stable disease patients (15% of the study population) survived for more than a year and one of these patients remains in follow-up.

RESULTS

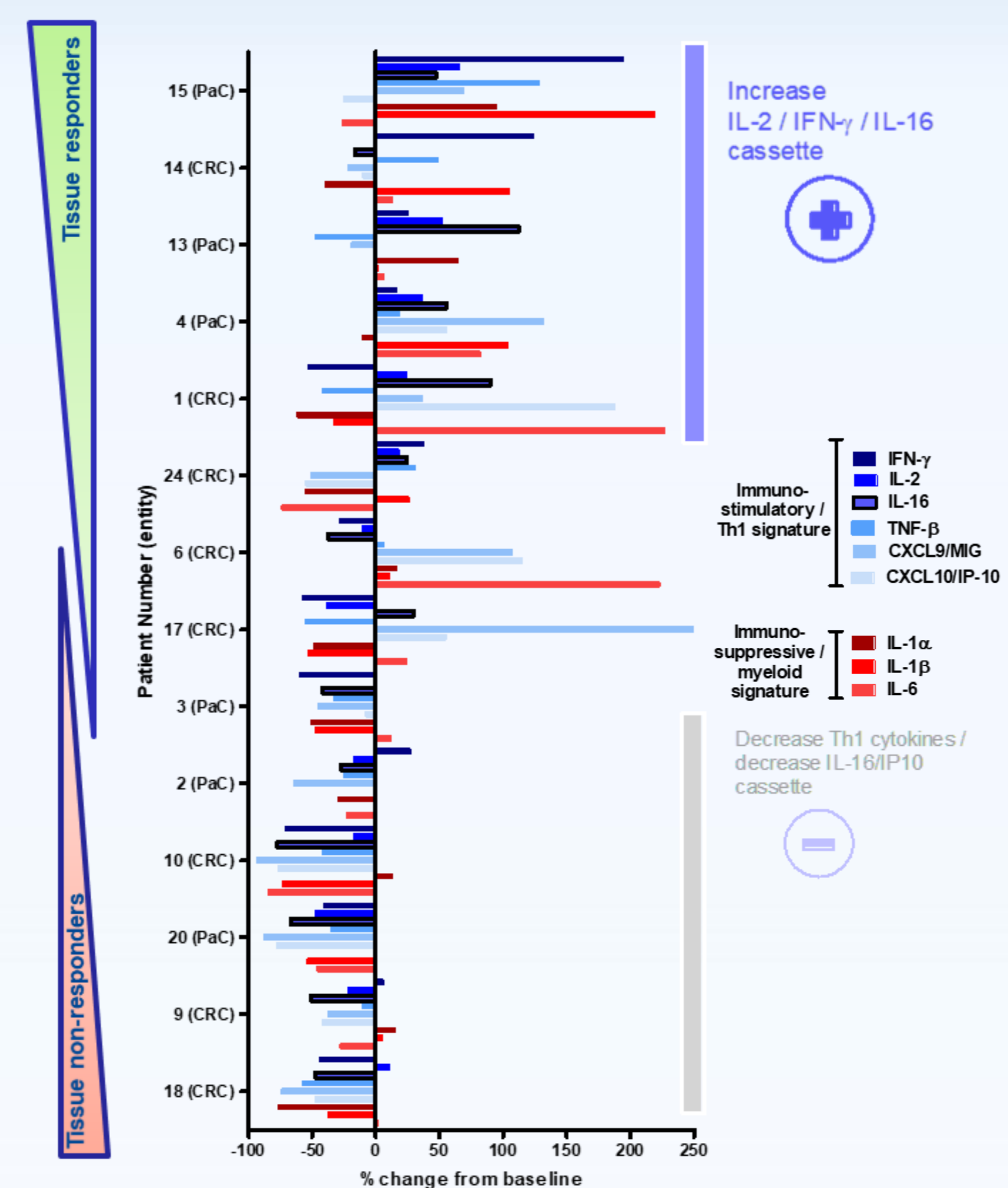


Figure 3: Cytokine tissue response following 2 weeks of NOX-A12 monotherapy

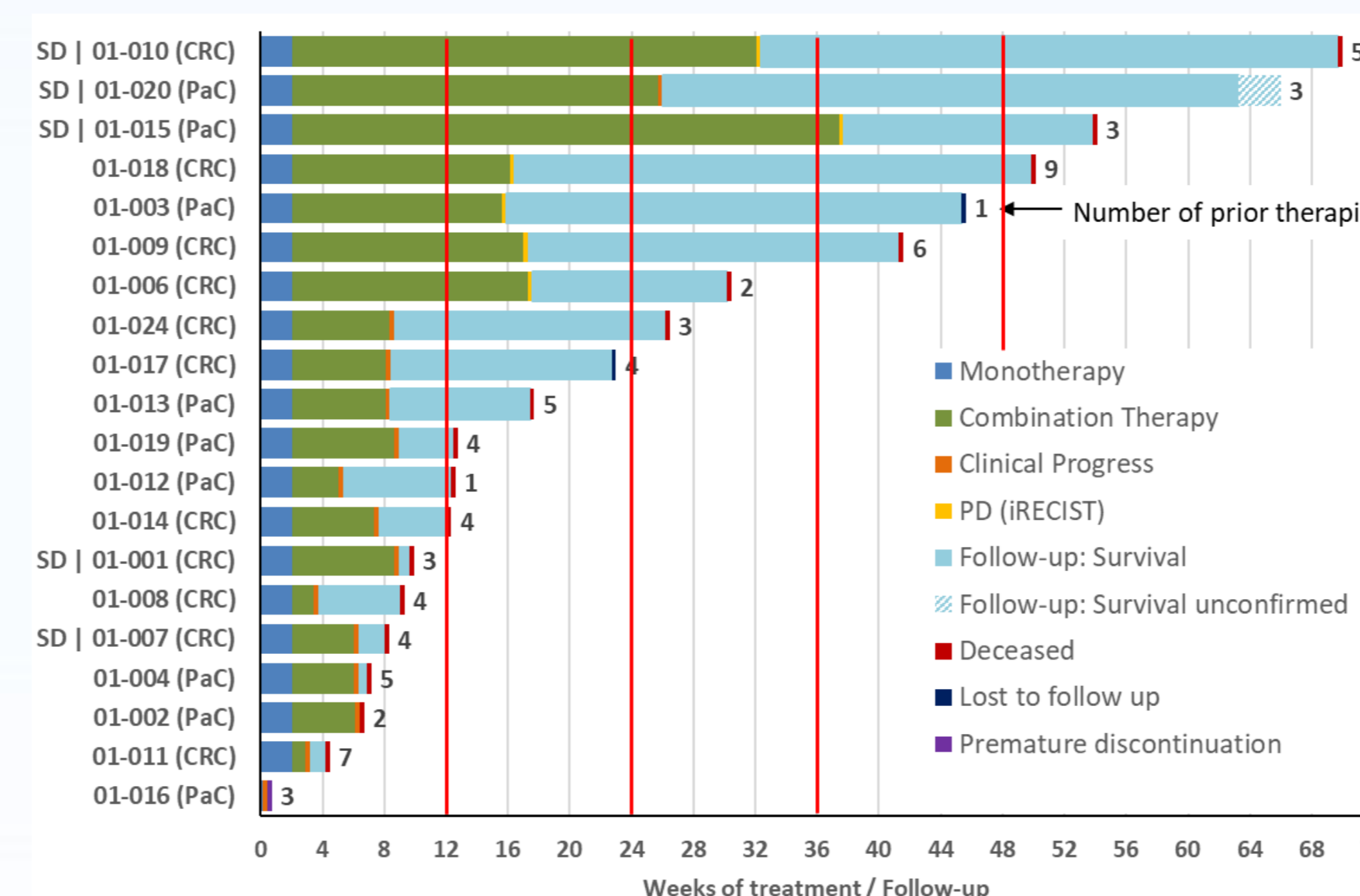


Figure 4: Patient time on study

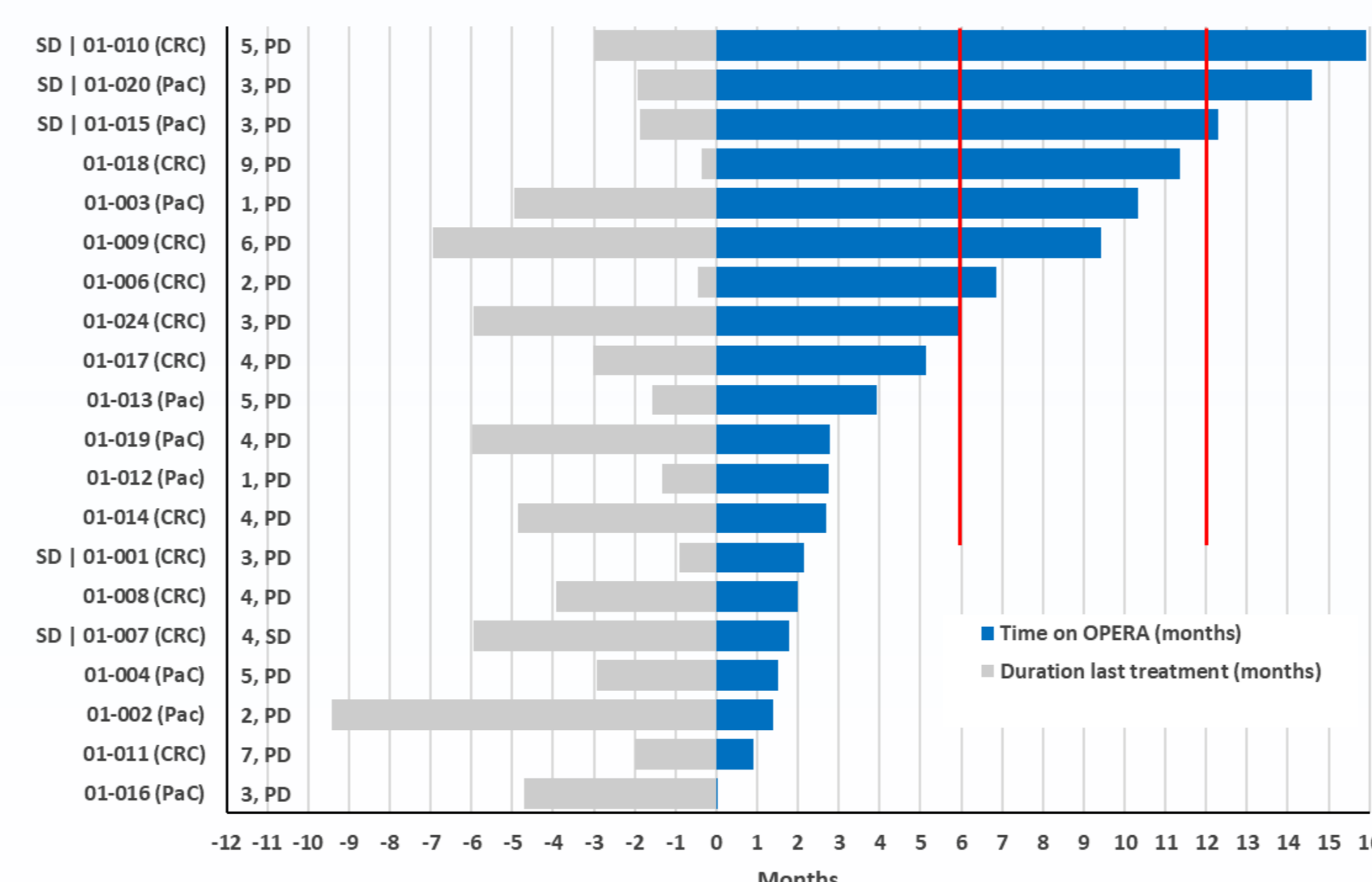


Figure 5: Patient time on study and time on previous therapy

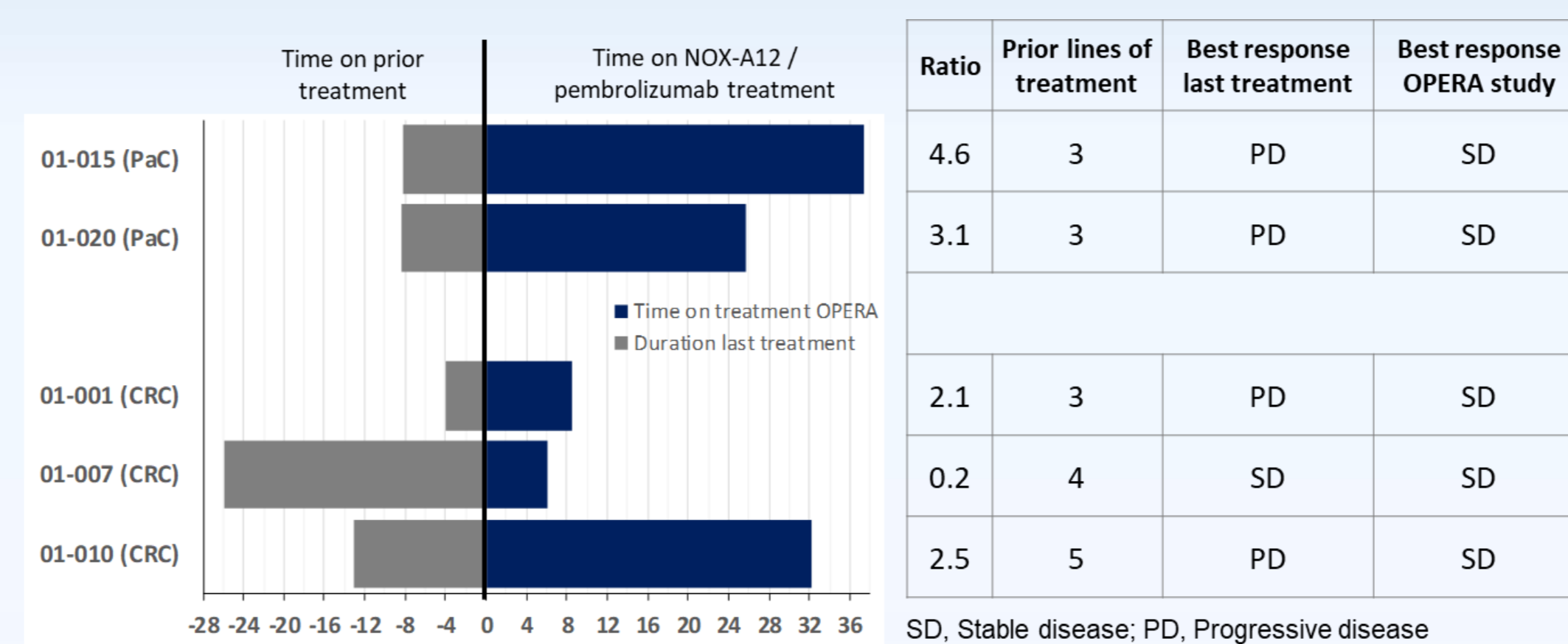


Figure 6: Patient time on NOX-A12/ pembrolizumab treatment and time on previous therapy; stable disease observed in highly pretreated, rapidly progressing patients

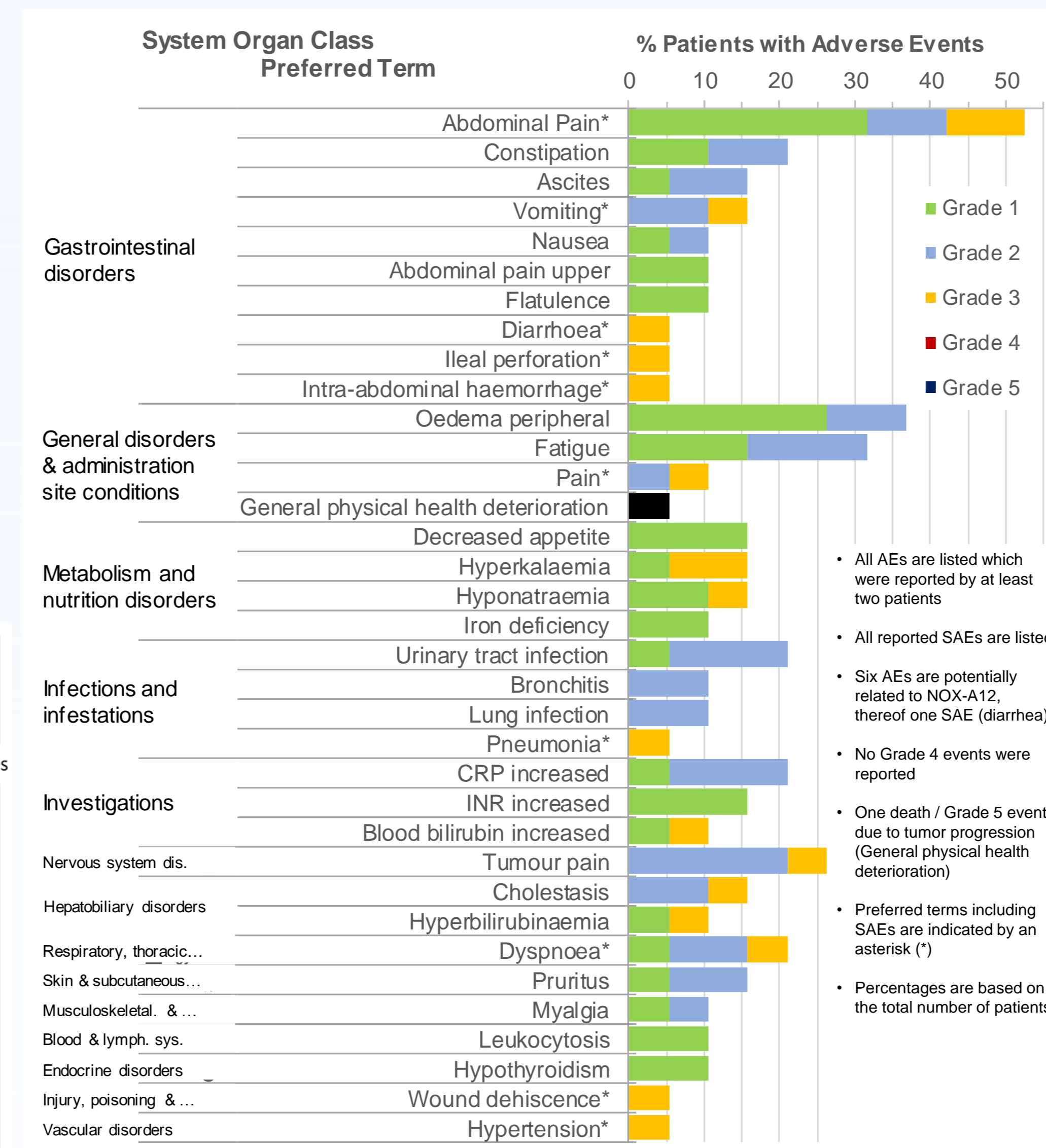


Figure 9: AE profile

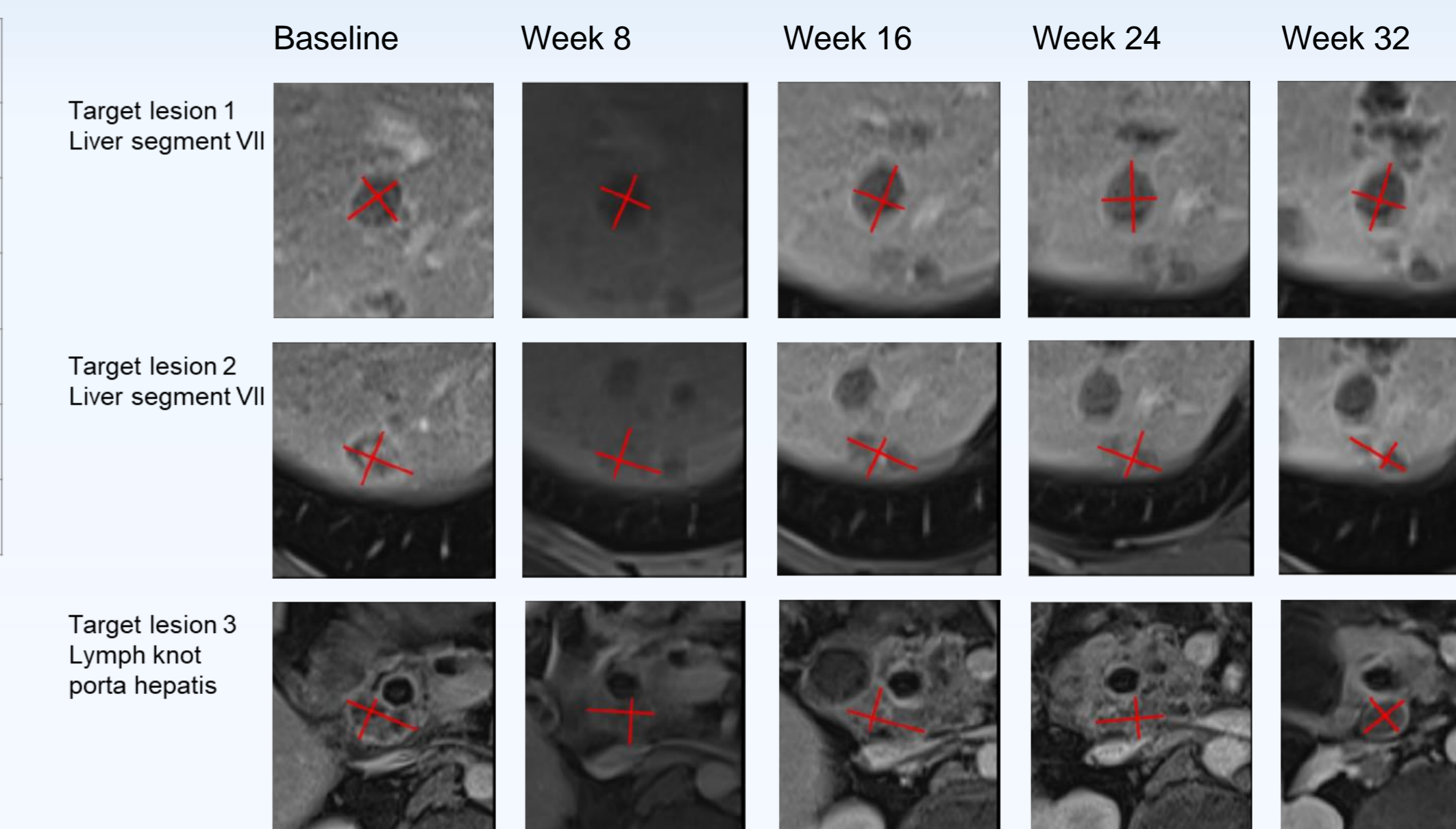


Figure 7: Target lesions during therapy, patient 015

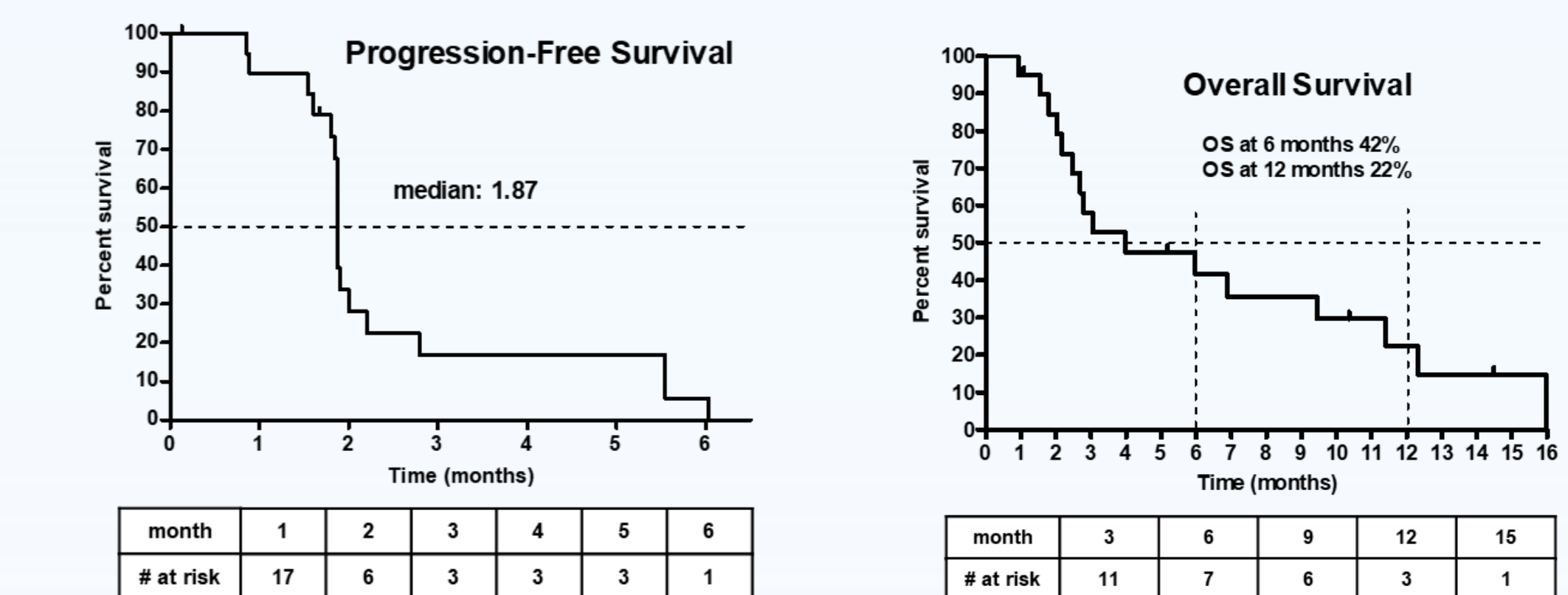


Figure 8: Progression-free and overall survival in patients receiving the NOX-A12 + pembrolizumab combination therapy, all patients

The development of target lesions throughout therapy is exemplarily shown for pancreatic adenocarcinoma patient 015 (Fig. 7). Median progression-free survival was 1.87 months, overall survival was 42% at 6 months and 22% at 12 months (Fig. 8).

The AE profile in the study was comparable with the safety profile for pembrolizumab or typical for the underlying diseases colorectal and pancreatic cancer. Treatment with NOX-A12 monotherapy and in combination with pembrolizumab was safe and well tolerated, with 148 AEs in total, thereof 47.3% grade 1; 36.5% grade 2; 15.5% grade 3; no grade 4 and 0.7% grade 5 (Fig. 9).

CONCLUSION

In patients with microsatellite-stable metastatic pancreatic and colorectal cancer, with impaired immune systems and a high tumor load that have failed multiple prior lines of therapy, NOX-A12 plus pembrolizumab shows induction of immune response, stable disease in 25% of patients, and prolonged time on treatment vs. prior therapy for 35% of patients. Median progression-free survival was 1.87 months, overall survival was 42% at 6 months and 22% at 12 months. Three of the stable disease patients (15% of the study population) survived for more than a year and one of these patients remains in follow-up.

This study also supports the role of CXCL12 in resistance to immunotherapy. CXCL12 is abundantly present in tumor lesions. The extent of CXCL12 neutralization in tumor tissue correlates with a Th1 immune response and disease stabilization. Further studies of NOX-A12 in combination with Keytruda are warranted and there is ample scope to optimize the NOX-A12 dose regimen given the good safety and tolerability of the tested regimen.

ACKNOWLEDGEMENTS & DISCLOSURES

The study was sponsored by NOXXON Pharma AG. Merck Sharp & Dohme Corp., a subsidiary of Merck & Co., Inc., Kenilworth, NJ, USA provided pembrolizumab for the study. AF, DB, DE, JUJ and AM are employees of NOXXON and hold shares and/or options.

